



The Association of Minimally Invasive Gynecologic Surgeons

...dedicated to safe, state-of-the-art surgery and health life-styles for women of all ages

R. Wayne Whitted MD, MPH

Paul A. Pietro MD

8740 N Kendall Dr. Suite 101

Miami, Florida 33176

Phone: 305-596-3744

www.floridaamigos.com

Hydradenitis Suppurativa

Hidradenitis suppurativa is a chronic, recurring, abscessing disease occurring in the apocrine follicles and sweat glands. The disease tends to become chronic because of subcutaneous extension leading to induration, sinus, and fistula formation.

Frequency:

In the US: Hidradenitis suppurativa occurs more commonly in women and usually occurs in the third decade of life. One study by Brown et al determined the prevalence in industrialized countries to be 0.3-4%.

Internationally: The prevalence has not been accurately determined. The disease is found more commonly in the white and the black populations and is rarely observed in the Asian population.

Age: Hidradenitis suppurativa usually begins in the postpubertal age group, when the apocrine glands start developing. It is most common in the third decade of life, but the untreated disease may persist into the seventh decade.

Sex: The condition is more common in women. Sub-breast, armpit, and inguinal involvement is more common in females, whereas the perineal form is more common in men.

Site: Hidradenitis suppurativa is found in the following areas:

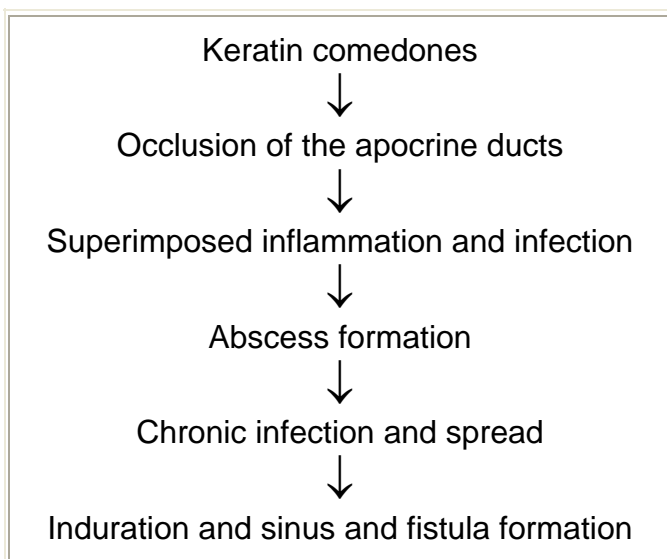
- Skin-bearing apocrine glands
- Axilla
- Groin
- Perineum
- Perianal region
- Buttocks
- Scrotum
- Infra-mammary region

Etiology: The exact cause of hidradenitis suppurativa has not been determined, although the following theories have been proposed:

- Folliculitis is observed in all patients with hidradenitis suppurativa; whether this is coincidental or causative has not been established.
- Local frictional trauma has been proposed to be one of the causative factors.

- Infective etiology
 - Streptococci, staphylococci, and *Escherichia coli* have been identified in the early stages of the disease; however, in the chronic relapsing stages, anaerobic bacteria and *Proteus* species have more commonly been isolated.
 - Whether the bacteria are the cause or the result of the disease has not been determined.
- Diabetes, impaired glucose intolerance, and obesity were observed in some patients with hidradenitis. Studies have shown that these entities are only incidental findings and not causative.
- Hormonal theory: Improvement and relapse after pregnancy and contraceptive pill intake suggest that low levels of estrogens cause a predisposition for hidradenitis suppurativa.
- Immune theory: Immunity in most patients is intact, but some patients demonstrate a defect in the T-cell lymphocytes.
- Genetic theory: Increased incidence in individuals with HLA-A1 and HLA-B8 has been demonstrated in some patients.
- Association tetrads: Hidradenitis is part of the tetrad of acne conglobata (cystic acne), pilonidal sinus, and perifollicular capitis.
- Cigarette smoking and lithium therapy have been identified as triggering factors for the disease.

Process of formation of condition:



Clinical:

The early lesions are solitary, painful pruritic nodules that may persist for weeks or months without any change. If subcutaneous extension occurs, it may appear as indurated plaques, which in lax skin, such as the axilla and groin, manifest as linear bands. Multiple sites may be simultaneously affected.

The nodules develop into pustules and eventually rupture externally, draining purulent material. Healing occurs with dense fibrosis, and recurrences crop up in and around the original site. This leads to chronic sinus formation, with intermittent release of serous, purulent, or bloodstained discharge. Ulceration

sometimes occurs, and the abscesses may burrow and rupture into the neighboring structures. Episodes of acute cellulitis are sometimes a feature and are accompanied by fever.

Regional enlarged lymph nodes are characteristically absent. Chronic axillary hidradenitis suppurativa usually causes a reduction of the normal axillary odor.

Severity and course of the disease are variable, but untreated hidradenitis suppurativa is typically a relentless progressive disease with acute exacerbations and remissions that lead to sinus tract formation and marked scarring.

Differential diagnoses include the following conditions:

- Infected cystic acne
- Lymphogranuloma venereum
- Developmental fistulae
- Crohn disease
- Furunculosis
- Scrofuloderma
- Actinomyces

Recurrent abscess formation and formation of chronic sinus and tracts with recurrence are the usual indications for surgery.

Contraindications: The acute abscess stage is a relative contraindication for curative surgery, which can be performed subsequent to a short course of antibiotic therapy.

Lab Studies:

- Blood tests
 - A complete blood cell count identifies the underlying anemia associated with the chronic disease.
 - Blood sugar tests identify associated diabetes.
- Microbiology
 - In the acute stages, the isolated organisms include the coagulase negative staphylococci, *E coli*, *Streptococcus milleri*, and the anaerobic *Bacteroides* species. *Proteus* species have been isolated from patients with chronic conditions.
 - Staphylococci have been shown to be the transient bacteria in the acute initial stages, whereas *S milleri* is the predominant organism in the chronic stages.

Staging: The disease can be divided into the following 3 clinical stages:

- Stage 1: Single or multiple abscesses form, without sinus tracts and scarring.
- Stage 2: Recurrent abscesses form, with tract formation and scarring. There may be single or multiple widely separated lesions.
- Stage 3: Diffuse or near-diffuse involvement or multiple interconnected tracts and abscesses are observed across the entire area.

Medical therapy: Treatment depends upon the stage of the disease. Early lesions are usually treated by medical therapy, whereas the patient with long-standing indolent disease requires surgical therapy.

Nonspecific treatment measures include good hygiene, weight reduction, use of antiseptic detergents, and avoidance of tight-fitting clothes.

- Acute-stage treatment options
 - Antibiotics: A short course of antibiotics for a period of 2 weeks is usually advisable. The antibiotics used include a combination of erythromycin and metronidazole, minocycline, or clindamycin. Cephalosporins and penicillins can also be used.
 - Intralesional steroids: Intralesional injection of steroids (eg, triamcinolone 5-10 mg diluted with water) causes the early lesions to involute within 12-24 hours.
- Chronic relapsing–stage treatment options
 - Long-term antibiotics: Long-term administration of erythromycin and tetracycline has been used to treat the chronic stages and is shown to reduce the relapse rate. However, the efficacy of the antibiotics may be lost after long-term use. Efficacy can usually be regained by stopping the drug for a month and restarting it.
 - High-dose systemic steroids (eg, prednisolone 60 mg/d) are useful as adjuvants to antibiotics, and they act by reducing the inflammatory process.
 - Estrogens: Contraceptive pills (eg, 50 mcg ethynyl estradiol) and the combination of estrogens with 100 mg of cyproterone acetate have been used.
 - Retinoids: These have been shown to be effective in the chronic disease. Isotretinoin, at a dose of 1 mg/kg/d, is administered for 4 months. Etretinate, at a dose of 0.5 mg/kg/d for a period of 6 months, is used for patients whose conditions are unresponsive to isotretinoin. Retinoids are teratogenic, and pregnancy is prevented by the use of contraception. Approximately 40% of patients show good response to retinoids.
- Other therapeutic agents that have been used with limited success include cisplatin, methotrexate, 5-alpha reductase inhibitors, and TNF-alpha inhibitors. Infliximab has been used in patients having Crohn disease and associated hidradenitis suppurativa.

Surgical therapy:

- Stage 1 options include incision and drainage, followed by antibiotics.
- Stage 2 and some stage 3 options include minor procedures.
 - Exteriorization and laying open of tracts and electrocoagulation

- Excision and primary closure, such as the Pollock procedure
- Stage 3 options include total wide excision and healing with secondary intention or flaps and grafts.
- Closure of defects is achieved by the following:
 - Z-plasty
 - Skin grafts
 - Thiersch split-thickness grafts
 - Meshed grafts
 - Wolfe full-thickness grafts
 - Flaps
 - Rotation flaps
 - Free flaps
 - Biosynthetic agents, like Biobrane and Integra, have also been recently used.

Preoperative details:

- Be aware of the possibility of associated systemic abnormalities.
- Perform routine preoperative assessment for surgery and anesthesia, including cardiac, respiratory, and renal assessments.
- Order antibiotics to treat the acute exacerbations before surgery.
- Order prophylactic antibiotics before surgery.
- Warn patients of the likelihood of a large raw area, which will require prolonged postoperative dressings.

Intraoperative details:

- Perform a wide excision, with a margin of 1.5 cm all around the lesion.
- Perform intraoperative mapping of the sinus tracts with methyl violet, which reduces recurrence rates.
- In the genital and perianal area, primary closure is to be avoided, and healing by secondary intention is advocated.
- Axilla: Total excision with transverse primary closure (ie, the Pollock procedure) is usually possible.

Postoperative details:

- Postoperative care
 - Regular and prolonged use of postoperative dressings is necessary to aid secondary healing.
 - Healing can be hastened by the use of silastic foam dressings.
 - Use of Betadine and chlorhexidine dressings and compression have been shown to be of benefit.
- Postoperative complications
 - Patients can develop general complications such as pneumonia, deep venous thrombosis (DVT), and infection. Administer routine perioperative DVT and antibiotic prophylaxis.
 - Active physiotherapy, breathing exercises, and early ambulation are encouraged.
 - Postoperative complications specific to the procedure include wound breakdown,

- hematoma formation, wound infection, and graft rejection and failure.
- The overall complication rate is 17-20%.

Follow-up care: Patients are monitored in the clinic at regular intervals for at least 6 months before they can be declared to be cured.

The complications of long-standing untreated disease include the following:

- Fistulae formation into the urethra, bladder, rectum, or peritoneum has been reported.
- Sequelae of chronic infection such as secondary anemia, hypoproteinemia, amyloidosis, and renal disease can occur in chronic disease.
- Joint disease.
- Chronic fatigue and depression are observed.
- Scarring of the tissue can lead to lymphatic obstruction and swelling of the limbs and joints
- Marjolin ulcer (squamous cell carcinoma) has been reported in long-standing chronic disease.
- Scrotal elephantiasis has been reported.

Recurrence does arise, and reported rates vary by 30-50%. One series reports a 100% recurrence rate with incision and drainage alone, 42% recurrence with limited excision, and 27% recurrence after radical excision.

Reassessment for several months in the follow-up clinic is required before cure can be assumed with certainty.

Bibliography

- Alexander SJ: Squamous cell carcinoma in chronic hidradenitis suppurativa: a case report. *Cancer* 1979 Feb; 43(2): 745-8.
- Barth JH, Layton AM, Cunliffe WJ: Endocrine factors in pre- and postmenopausal women with hidradenitis suppurativa. *Br J Dermatol* 1996 Jun; 134(6): 1057-9.
- Bell BA, Ellis H: Hidradenitis suppurativa. *J R Soc Med* 1978 Jul; 71(7): 511-5
- Bhalla R, Sequeira W: Arthritis associated with hidradenitis suppurativa. *Ann Rheum Dis* 1994 Jan; 53(1): 64-6.
- Brook I, Frazier EH: Aerobic and anaerobic microbiology of axillary hidradenitis suppurativa. *J Med Microbiol* 1999 Jan; 48(1): 103-5.
- Brown TJ, Rosen T, Orenge IF: Hidradenitis suppurativa. *South Med J* 1998 Dec; 91(12): 1107-14.
- Conway H: Surgical treatment of chronic hidradenitis suppurativa. *Surg Gynaecol Obstet* 1952; 95: 455-463.
- Dvorak VC, Root RK, MacGregor RR: Host-defense mechanisms in hidradenitis suppurativa. *Arch Dermatol* 1977 Apr; 113(4): 450-3.
- Finley EM, Ratz JL: Treatment of hidradenitis suppurativa with carbon dioxide laser excision and second-intention healing. *J Am Acad Dermatol* 1996 Mar; 34(3): 465-9.
- Fitzsimmons JS, Guilbert PR, Fitzsimmons EM: Evidence of genetic factors in hidradenitis suppurativa. *Br J Dermatol* 1985 Jul; 113(1): 1-8
- Frohlich D, Baaske D, Glatzel M: [Radiotherapy of hidradenitis suppurativa--still valid

today?]. *Strahlenther Onkol* 2000 Jun; 176(6): 286-9.

- Harrison BJ, Kumar S, Read GF: Hidradenitis suppurativa: evidence for an endocrine abnormality. *Br J Surg* 1985 Dec; 72(12): 1002-4
- Highet AS, Warren RE, Weekes AJ: Bacteriology and antibiotic treatment of perineal suppurative hidradenitis. *Arch Dermatol* 1988 Jul; 124(7): 1047-51.
- Hogan DJ, Light MJ: Successful treatment of hidradenitis suppurativa with acitretin. *J Am Acad Dermatol* 1988 Aug; 19(2 Pt 1): 355-6.
- Jemec GB, Faber M, Gutschik E: The bacteriology of hidradenitis suppurativa. *Dermatology* 1996; 193(3): 203-6.
- Jemec GB: Long-term results of isotretinoin in the treatment of 68 patients with hidradenitis suppurativa. *J Am Acad Dermatol* 1999 Oct; 41(4): 658.
- Jemec GB, Heidenheim M, Nielsen NH: The prevalence of hidradenitis suppurativa and its potential precursor lesions. *J Am Acad Dermatol* 1996 Aug; 35(2 Pt 1): 191-4
- Jemec GB: The symptomatology of hidradenitis suppurativa in women. *Br J Dermatol* 1988 Sep; 119(3): 345-50
- Joseph MA, Jayaseelan E, Ganapathi B: Hidradenitis suppurativa treated with finasteride. *J Dermatolog Treat* 2005 Apr; 16(2): 75-8.
- Konig A, Lehmann C, Rompel R: Cigarette smoking as a triggering factor of hidradenitis suppurativa. *Dermatology* 1999; 198(3): 261-4.
- Kurzen H, Jung EG, Hartschuh W: Forms of epithelial differentiation of draining sinus in acne inversa (hidradenitis suppurativa). *Br J Dermatol* 1999 Aug; 141(2): 231-9.
- Lane JC: hidrosdenitis axillare of Verneuil. *Arch Dermatol Sphilol* 1939; 39: 108.
- Lapins J, Sartorius K, Emtestam L: Scanner-assisted carbon dioxide laser surgery: a retrospective follow-up study of patients with hidradenitis suppurativa. *J Am Acad Dermatol* 2002 Aug; 47(2): 280-5.
- Letterman G, Schurter M: Surgical treatment of hyperhidrosis and chronic hidradenitis suppurativa. *J Invest Dermatol* 1974 Jul; 63(1): 174-82.
- Melkun ET, Few JW: The use of biosynthetic skin substitute (Biobrane) for axillary reconstruction after surgical excision for hidradenitis suppurativa. *Plast Reconstr Surg* 2005 Apr 15; 115(5): 1385-8.
- Mortimer PS, Dawber RP, Gales MA: A double-blind controlled cross-over trial of cyproterone acetate in females with hidradenitis suppurativa. *Br J Dermatol* 1986 Sep; 115(3): 263-8.
- Moschella SL: Hidradenitis suppurativa. Complications resulting in death. *JAMA* 1966 Oct 3; 198(1): 201-3.
- Mustafa EB, Ali SD, Kurtz LH: Hidradenitis suppurativa: review of the literature and management of the axillary lesion. *J Natl Med Assoc* 1980 Mar; 72(3): 237-43.
- O'Loughlin S, Woods R, Kirke PN: Hidradenitis suppurativa. Glucose tolerance, clinical, microbiologic, and immunologic features and HLA frequencies in 27 patients. *Arch Dermatol* 1988 Jul; 124(7): 1043-6.
- Paletta F X: Hidradenitis suppurativa: pathological study and use of skin flaps. *Plast Reconstr Surg* 1963; 31: 307.
- Pollock WJ, Virnelli FR, Ryan RF: Axillary hidradenitis suppurativa. A simple and effective surgical technique. *Plast Reconstr Surg* 1972 Jan; 49(1): 22-7.
- Ramasastry SS, Conklin WT, Granick MS: Surgical management of massive perianal hidradenitis suppurativa. *Ann Plast Surg* 1985 Sep; 15(3): 218-23.
- Ritz JP, Runkel N, Haier J: Extent of surgery and recurrence rate of hidradenitis suppurativa. *Int J Colorectal Dis* 1998; 13(4): 164-8

- Rompel R, Petres J: Long-term results of wide surgical excision in 106 patients with hidradenitis suppurativa. *Dermatol Surg* 2000 Jul; 26(7): 638-43
- Rose RF, Goodfield MJ, Clark SM: Treatment of recalcitrant hidradenitis suppurativa with oral ciclosporin. *Clin Exp Dermatol* 2006 Jan; 31(1): 154-5.
- Shelly WB, Cahn: Pathogenesis of hidradenitis suppurativa in man. Experimental and histological observations. *Arch Dermatol* 1955; 72: 562.
- Stellon AJ, Wakeling M: Hidradenitis suppurativa associated with use of oral contraceptives. *BMJ* 1989 Jan 7; 298(6665): 28-9.
- Sullivan TP, Welsh E, Kerdel FA: Infliximab for hidradenitis suppurativa. *Br J Dermatol* 2003 Nov; 149(5): 1046-9
- Tennant F Jr, Bergeron JR, Stone OJ: Anemia associated with hidradenitis suppurativa. *Arch Dermatol* 1968 Aug; 98(2): 138-40.
- Trent JT, Kerdel FA: Tumor necrosis factor alpha inhibitors for the treatment of dermatologic diseases. *Dermatol Nurs* 2005 Apr; 17(2): 97-107.
- Venturini R, Ruggieri V, Stellar A: The after-effect of movement induced with a rotating spiral (spiral after-effect): reliability and correlation with personality characteristics. *Boll Soc Ital Biol Sper* 1974 Feb 15; 50(3): 118-24.
- Verneuil AS: Etudes sur les tumor de la peau. *Arch Gen Med* 1854; 94: 693.
- Von Der Werth JM, Williams HC, Raeburn JA: The clinical genetics of hidradenitis suppurativa revisited. *Br J Dermatol* 2000 May; 142(5): 947-53